



restoration realized

Experience with fat grafting as a soft-tissue filler shows that it also has regenerative effects on aged and damaged skin

Cheryl Guttman Krader

SENIOR STAFF CORRESPONDENT

Autologous fat grafting is a safe, effective and durable technique for soft-tissue augmentation, but more importantly, the fat grafts also have regenerative activity that has implications for restoring aged and damaged skin to a healthier condition, says Sydney R. Coleman, M.D.

"Fat grafts are much more than fillers that add volume and recreate fullness. They also stimulate tissue repair and rejuvenate skin quality,

Dr. Coleman says he attributes the regenerative benefits of fat grafting to the presence of adipose-derived stem cells and growth factors in the fat grafts.

and my observations are that these benefits are progressive and long-lasting," says Dr. Coleman, clinical assistant professor, department of plastic surgery, New York University Medical Center, New York.

Noting that the regenerative properties of fat grafting were first described in the literature about a century ago, Dr. Coleman says his interest in this aspect of the practice was raised when a patient of his who received a 1 cc fat graft to augment a defect in the nose benefited with resolution of a long-standing scar.

Patients receiving autologous fat grafts into different areas of the face as a cosmetic procedure for volume restoration also developed improvements in skin color and reductions in pore size and wrinkles, he says. Another patient had remarkable improvement of chemical peeling-induced scarring on the hands and forearms, and fat injection around the coccyx to provide cushioning in a patient with idiopathic lipodystrophy benefited with healing of a longstanding ulcer over her coccyx. Another patient who had undergone radical local excision and radiation therapy for rhabdomyosarcoma of the masseter showed improvement in skin quality and regrowth of beard hair after receiving a series of three fat injections.



Dr. Coleman

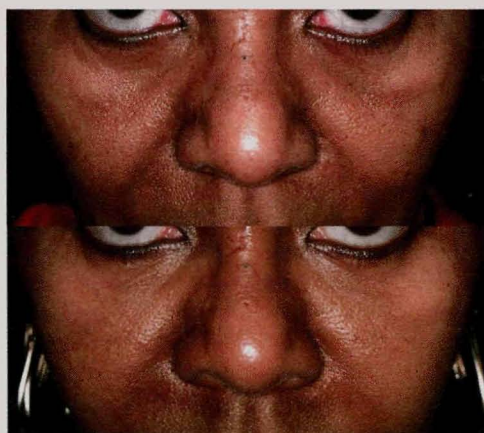"I think this latter case provides the most concrete clinical evidence that fat grafting has regenerative properties because radiation therapy causes progressive, unremitting tissue damage that does not heal with time. Whereas the irradiated tissue in this patient had been hard and sclerotic, after fat grafting, it became pliable and felt natural to touch," Dr. Coleman says.

ANIMAL EXPERIMENTS Supported by a research grant from the National Endowment for Plastic Surgery, Dr. Coleman established the regenerative effects of fat grafting in laboratory experiments. First, he investigated the effects of human fat grafts on irradiated tissue in an animal model (Sultan SM, Stern CS, Allen RJ Jr, et al. *Plast Reconstr Surg.* 2011;128(2):363-372). Dorsal skin of wild-type immunocompetent mice was distracted from the body and then exposed to 45 Gy radiation.

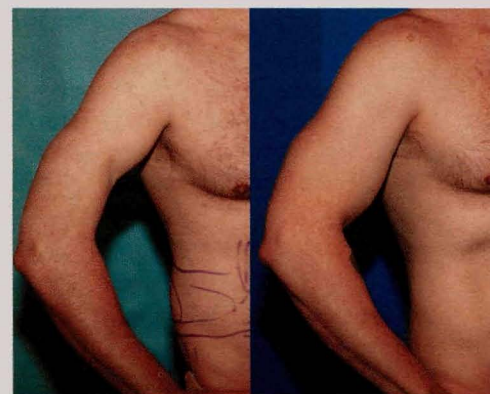
During four weeks of follow-up, the animals developed visible damage, including tissue thickening, hyperpigmentation and progressive ulceration, Dr. Coleman says. The dorsal areas were then injected with either human fat grafts or saline as a control; the grafting was performed using Dr. Coleman's structural fat grafting technique in which small aliquots of fat are diffusely delivered into the subcutaneous space. The animals were followed with serial photography and divided into two groups for sacrifice and histological evaluation at four and eight weeks.

Dr. Coleman reports that only animals receiving the fat injections exhibited clinical improvement in their skin appearance that was manifested by reduction of alopecia, normalization of skin color and texture, and ulceration healing. Histological studies provided evidence of the molecular basis for the observed changes. Compared with controls, fat injection was associated with downregulation of the expression of Smad3, a profibrotic protein, and CD31 staining showed a decrease in pathologic angiogenesis that occurs in response to radiation. However, animals receiving the fat grafts had an increase in normal vascularity and reductions in both epidermal thickening and the scar index as measured by picrosirius red staining, Dr. Coleman says.

BURN-SCAR STUDIES Dr. Coleman and colleagues performed a similar experiment in an animal model of burn scars (Sultan



The lower eyelids in a patient who had a previous lower eyelid blepharoplasty. Before (above) and 14 months after one session of placing 4 cc of Coleman processed fat into each lower eyelid. Note the decrease in the size of her pores as well as an improvement in color and texture of the skin, Dr. Coleman says. (Photos credit: Sydney Coleman, M.D.)



A patient who experienced a right biceps tear four years ago. He was curling a free-weight when he had a pain in his biceps and noticed "bubbling" of his biceps. He had no treatment of the tear, and it gradually atrophied to leave a deformity (left). One year after the second placement of structural fat into the biceps (right), the patient says he feels that his strength has returned to the involved biceps. (Photos credit: Sydney Coleman, M.D.)

SM, Barr JS, Butala P, et al. *J Plast Reconstr Aesthet Surg.* 2012;65(2):219-227). Full-thickness injury was created using Dr. Coleman's established murine model of thermal injury, and two weeks later, fat or saline was injected subcutaneously at the site of injury.

The animals were divided into two groups for evaluation after four or eight weeks. Doppler scanning established there was significantly greater blood flow in the fat-grafted animals compared with the controls. Histological evaluations of tissue from sacrificed animals showed that compared with the control group, tissue from the fat-treated animals had significantly higher levels of vasculogenic proteins and significantly lower levels of molecular markers of fibrosis.

Consistent with these findings, tissue staining showed significantly upregulated vascularity at four weeks in the fat-treated animals and a significantly lower scar index at eight weeks compared with the controls.

Dr. Coleman says he attributes the regenerative benefits of fat grafting to the presence of adipose-derived stem cells and growth factors in the fat grafts.

"Every time we graft fat, we are grafting stem cells. Therefore, we are now focusing on trying to isolate these primitive cells from fat tissue and investigating their therapeutic use," he says. ◀