

The Anatomy of the Aging Face: Volume Loss and Changes in 3-Dimensional Topography

Sydney R. Coleman, MD; Rajiv Grover, BSc, MB BS, MD, FRCS (Plast)

Dr. Coleman is Assistant Professor of Plastic Surgery in the Department of Surgery at New York University School of Medicine, New York, NY.

Dr. Grover is Consultant Plastic and Aesthetic Surgeon, King Edward VII Hospital, London, UK.

Facial aging reflects the dynamic, cumulative effects of time on the skin, soft tissues, and deep structural components of the face, and is a complex synergy of skin textural changes and loss of facial volume. Many of the facial manifestations of aging reflect the combined effects of gravity, progressive bone resorption, decreased tissue elasticity, and redistribution of subcutaneous fullness.

A convenient method for assessing the morphological effects of aging is to divide the face into the upper third (forehead and brows), middle third (midface and nose), and lower third (chin, jawline, and neck). The midface is an important factor in facial aesthetics because perceptions of facial attractiveness are largely founded on the synergy of the eyes, nose, lips, and cheek bones (central facial triangle). For aesthetic purposes, this area should be considered from a 3-dimensional rather than a 2-dimensional perspective, and restoration of a youthful 3-dimensional facial topography should be regarded as the primary goal in facial rejuvenation.

Recent years have seen a significant increase in the number of nonsurgical procedures performed for facial rejuvenation. Patients seeking alternatives to surgical procedures include those who require restoration of lost facial volume, those who wish to enhance normal facial features, and those who want to correct facial asymmetry. Important factors in selecting a nonsurgical treatment option include the advantages of an immediate cosmetic result and a short recovery time.

(Aesthetic Surg J 2006;26(suppl):S4-S9.)

Aging of the human face is the result of both superficial textural wrinkling of the skin and changes in the 3-dimensional (3-D) topography of the underlying structures. The skin, soft tissues (subcutaneous fat, muscle, and fascia), and structural support (bone and teeth) are individually affected by the aging process, but they also act in dynamic unison to determine the phenotypic presentation of the face throughout life. The major forces contributing to facial aging include gravity, skeletal remodeling, subcutaneous fat redistribution and loss, hormonal imbalance, chronic solar exposure, and smoking. Other environmental factors that are purported to affect facial appearance include mental stress, diet, work habits, drug abuse, and disease.

Structural Components of Facial Aging

Skeletal structure

Aging of the craniofacial skeleton is not merely the result of bone atrophy but is also due to a change in the relative dynamics of bone expansion and bone loss.¹

There is an appreciable reduction in facial height, which is mainly due to changes in the maxilla and mandible, and a modest increase in facial width and depth. The orbits increase in size, whereas the maxilla decreases in size, compounding the inferior displacement of the malar fat pad and accentuation of the nasolabial fold.² Maxillary resorption can also lead to a loss of support in the upper lip, which contributes to perioral wrinkling. In the mandible, tooth loss causes marked resorption of the alveolar ridge, and the shape and projection of the chin also change with age. There is a general coarsening of mandibular bony protuberances at the points of insertion of masticatory muscles (eg, the gonial angle and inferior edge of the zygomatic eminence), and a general softening elsewhere.

Subcutaneous fat distribution

The youthful face is characterized by a diffuse, balanced distribution of superficial and deep fat, which confers a well-rounded 3-D topography that is delineated by a series of arcs and convexities.^{3,4} Viewed frontally, the

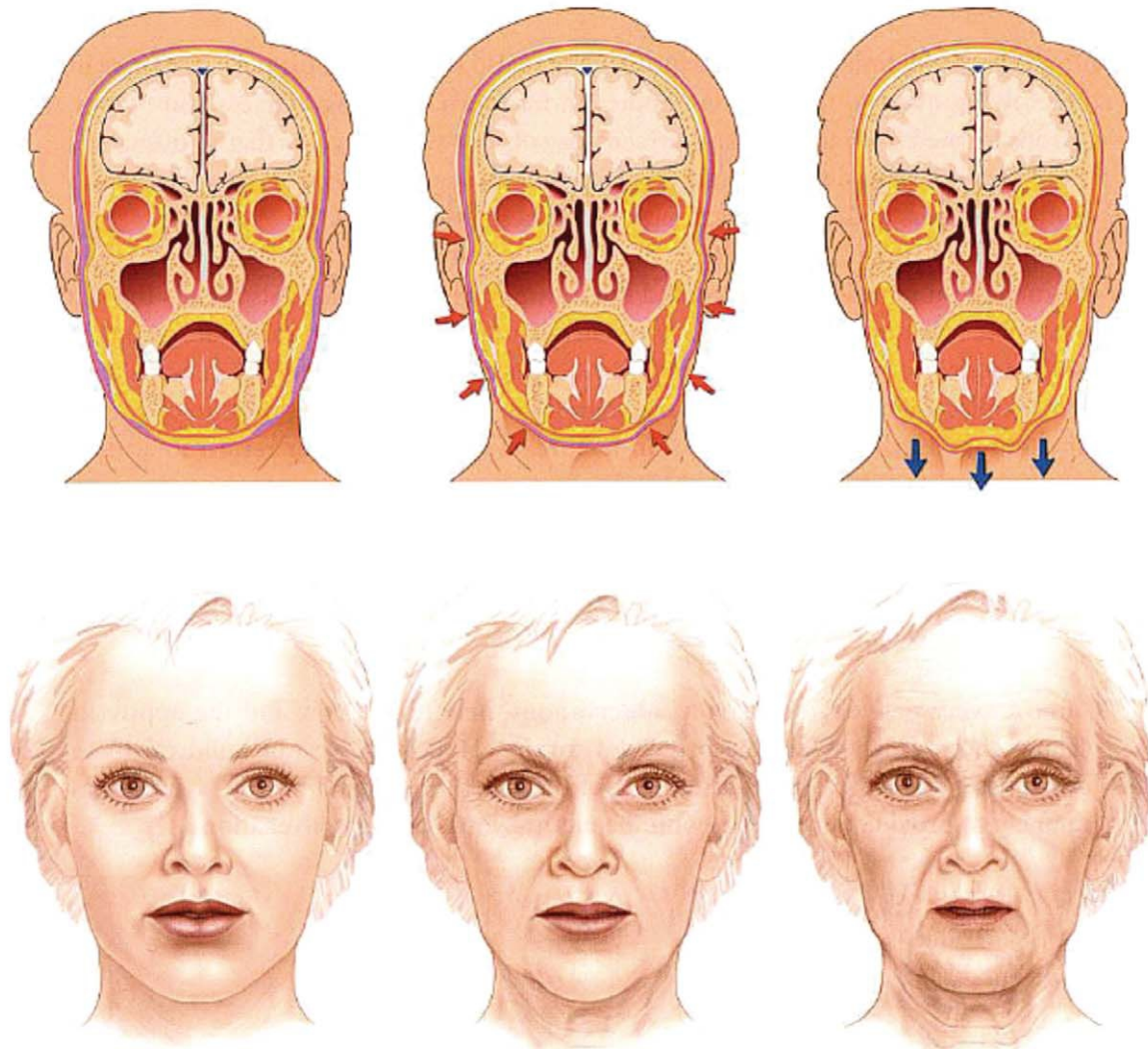


Figure 1. Coronal sections illustrating the loss of facial fullness that occurs with age. In the young face (left), the subcutaneous fat deposits (yellow) are masked by the fullness provided by extracellular colloidal fluids (purple). With advancing age, progressive loss of facial fullness causes the subcutaneous fat deposits and underlying soft tissue and skeletal structures to become more evident (center); involuntional exposure of fat deposits in the jowl and chin gives the impression of descent (right). Reproduced with permission from Coleman, 2004.⁶

primary arc of the jawline, convexities of the temples, and multiple smaller secondary arcs of the lips are evident. In profile, 3 primary arcs are the most definitive features of youth: the lateral cheek projection (the “ogee” curve), extending as an unbroken convex line from the lower eyelid to the cheek; the arc of the jawline, extending from the lateral mandible to the mentum; and the arc of the forehead.⁵

Facial aging is associated with loss of soft tissue fullness in certain areas (periorbital, forehead, malar, temporal, mandibular, mental, glabellar, and perioral sites) and persistence or hypertrophy of fat in others (submental, lateral nasolabial fold and labiomental crease, jowls, infraorbital fat pouches, and malar fat pad).^{6,7}

Magnetic resonance imaging (MRI) has been used to establish that the percentage increase in fat in the upper third relative to the remainder of the midface was significantly greater in old subjects (N = 10), compared to young subjects (N = 10).⁷ However, MRI scanning technology requires subjects to adopt a prone position, thus the direction of gravitational pull on the cheek mass during scanning is different from that exerted when an individual is in the upright position. The hypertrophic cheek area would be expected to lie further down the face when the subjects were upright. Ideally, longitudinal imaging studies in the same patients over a lifetime would further the understanding of the dynamics of fat distribution in facial aging.

In addition to redistribution of facial fat and concomitant loss of surrounding fullness, the fat pockets become more discernible as separate entities, as do many of the underlying facial structures, such as the submaxillary glands and bony protuberances (Figure 1).⁶ With age, the malar fat pad gradually slides forward and down to bulge against the nasolabial crease, giving rise to the prominence of the nasal fold in the aged face.⁸ This redistribution and demarcation of fat gives the senile face an unbalanced appearance. Skin wrinkling occurs at some sites (periorbital and perioral areas) due to the repeated underlying muscle action to give a progression from dynamic rhytids initially to static rhytids as the skin changes become permanent. Elsewhere (jowl, submental area, and nasolabial fold) sagging can occur due to a relative excess of skin and/or lack of elastic recoil as well as fat accumulation.⁶ Consequently, the defining arcs and convexities of youth are disrupted. From the front, the jawline appears scalloped, the temporal, buccal, and suborbital areas are hollow, and the lips are straight and angular. In profile, the primary arc of the cheek is broken, the mandibular arc is replaced by a jowl line, and the forehead and brow lose their anterior projection.

Morphological Manifestations of Facial Aging

Many of the facial manifestations of aging are the result of the combined effects of atrophy and loss of facial fullness, progressive bone resorption, decreased tissue elasticity, and gravity.^{6,9} The gradual loss of underlying soft tissue support and fullness is responsible for the soft-tissue descent and relative excess of facial skin associated with aging. A convenient method for assessing the morphological effects of aging is to divide the face into thirds.

Upper third (forehead and brows)

Progressive aging brings a loss of subcutaneous fullness to the forehead, brow, temple, and upper eyelid areas, which accentuates the underlying anatomic structures. The bony outline of the skull and supraorbital rims become more evident, as do the muscles of the brow (notably corrugator and procerus muscles), and the temporal blood vessels assume an increasingly tortuous appearance.⁶ Loss of temporal support to the lateral brow, coupled with loss of fullness in the upper eyelid, create the impression of brow ptosis,⁶ with the eyebrow seemingly descending to a position at or below the superior orbital rim.¹⁰ Weakening of the orbital septum may allow protrusion of intraorbital fat, thereby creating a more bony orbital anatomy.

In youth, the subcutaneous fullness of the forehead conceals the muscles of facial expression in this region. As this fullness between the muscles and the skin disappears with age, the intrinsic tone of the glabellar, procerus, and frontalis muscles gives rise to fixed wrinkles or folds. The combination of fixed glabellar frown lines, fixed transverse forehead furrows, temporal hollowing, a skeletonized supraorbital rim, and a relative excess of upper eyelid skin is responsible for creating the impression of upper facial aging. Different sides of the face can age differently, and such a phenomenon happens frequently. For example, in a single subject, the upper eyelid skin may hang on one eye, and involute into the orbit of the other eye.

Middle third (midface)

In the midface, age-related loss of subcutaneous fullness in the malar prominence and progressive buccal hollowing result in a less healthy facial proportion. Depletion of the infraorbital subcutaneous tissue accentuates the effect of intrinsic tone in the orbicularis oculi muscle on the overlying skin, giving rise to “crow’s feet” rhytids. As the overlying fullness dissipates with age, the inferior border of the orbicularis oculi muscle also becomes more evident and contributes to the development of the malar crescent over the zygomatic eminence (laterally) and the nasojugal fold (medially). Volume loss in the infraorbital area also leads to the emergence of formerly concealed infraorbital fat pads (“palpebral bags”) and accentuation of the tear-trough depression, running obliquely from the lateral nose at the level of the medial canthus down to the anterior malar cheek below the middle of the eyelid. Additionally, the minimal transverse depression that runs immediately below the eyelashes deepens with age and extends downwards toward the infraorbital rim.

Secondary to the loss of subcutaneous fullness, downward displacement of intraorbital fat over a weakened orbital septum creates a deeper and wider orbit and double convex deformity of the lower eyelid.¹¹ Loss of fullness between the orbicularis oculi muscle and the overlying skin of the lower eyelid brings these tissues into closer proximity and confers a darker coloration to the thin infraorbital skin, resulting in a tired eye appearance. Dark coloration of the infraorbital skin may, however, also be attributable to dermal melanin deposition.¹² Ptotic cheek fat descends to create the nasolabial fold, leaving behind a cheek concavity that is accentuated by depletion of malar fullness.

Aging also alters the cartilaginous nasal skeleton and soft tissue covering.¹³ Most of the loss of fullness occurs

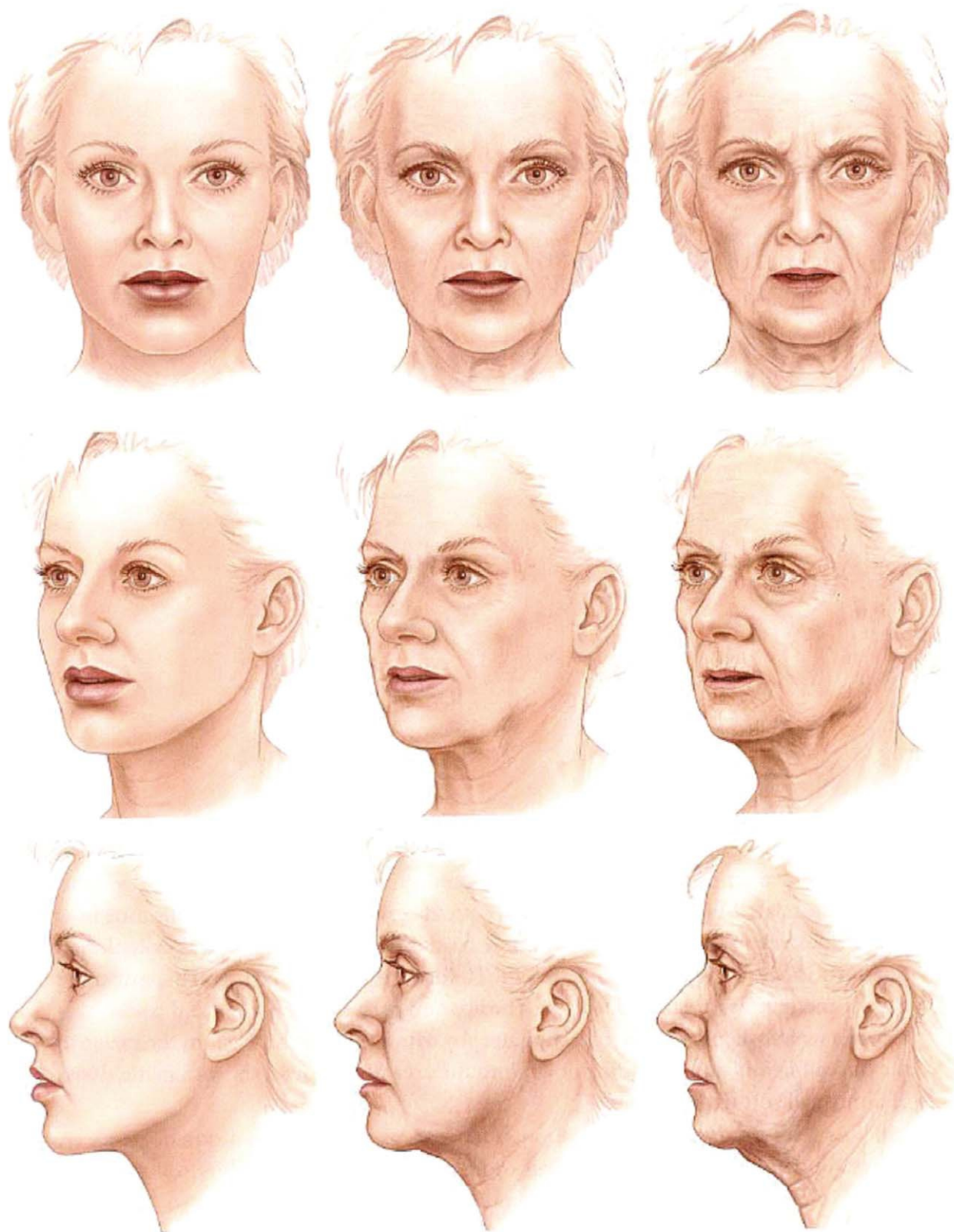


Figure 2. Aging of the female face, as represented by models representing an individual at ~20 years of age (left), ~50 years (center), and ~75 years (right). The primary event of aging is the loss of facial volume and the resulting involution and eventual descent of soft tissues. Reproduced with permission from Coleman, 2004.⁶

in the glabella, nasion, and upper dorsum (cephalic nose). Most of the changes that occur with aging in the nose take place in the glabella, nasion, and medial eyelid. Flattening of the medial forehead results in blunting of the nasofrontal angle, giving the illusion of increased nasal length. The attachments between the upper and lower lateral nasal cartilages weaken, causing progressive ptosis of the nasal tip. Pyriform remodeling affects the alar base and, in combination with upper maxillary resorption, results in a narrowing of the nasolabial angle and further accentuation of nasal tip ptosis. Chin pad ptosis, which occurs secondary to mandibular bone resorption, further contributes to the appearance of increased nasal projection and length.

Lower third (chin, jawline, and neck)

With progressively increasing skin laxity, depletion of malar and perioral fat deposits, and resorption of alveolar bone, a relative excess of skin occurs in the aging lower face, leading to loss of definition of the jawline. Loss of masseteric ligament support allows descent of facial fat to the mandibular border, leading to the formation of facial jowls.¹⁴ Upward retreat of the mandibular border results in exposure of the submental contents, including the submaxillary gland. As the lateral projection of mandibular fullness dissipates, the angle of the mandible appears to merge from the buccal region into the neck. In the chin, loss of lateral and inferior volume results in relative protrusion of the central chin, whereas lateral mental atrophy results in ptosis of the lateral chin, which can create the impression of chin widening when viewed from the front.⁶

As the subcutaneous fullness of the mandible recedes, the fat of the jowl, which was previously concealed by the surrounding soft tissues, is revealed. Ptosis of the unsupported skin, chin pad, and facial portion of the platysma muscle, coupled with the downward pull of the platysma muscle, leads to the development of the characteristic jowled “turkey neck” deformity. Protrusion of the large submental fat pad either between the two free borders of the platysma muscle or from behind the complete submental platysma cover further adds to this effect. In addition, contraction of the platysma muscle, caused in part by the need to support the deeper neck and floor of mouth structures, gives rise to vertical fibrous bands on the neck, whereas laxity in the overlying skin can create horizontal rhytides. As aging progresses, the hyoid bone and larynx gradually descend, resulting in loss or blunting of the cervico-mental angle.

Structural Rejuvenation of the Aging Face: The Need For Facial Rebalancing

Loss of facial fullness and the ensuing facial fat redistribution provides the visual clue to an individual’s age (Figure 2).⁶ Accordingly, the primary goal in any rejuvenation procedure should be to restore the ample, balanced distribution of facial fullness that exemplifies the youthful face.⁴ The fat compartmentalization of the aging face must be smoothed over, and the former primary arcs and convexities of youth, rebuilt.

Most conventional face lift procedures incorporate lifting and tightening techniques to defy the facial soft-tissue descent that results from atrophy and loss of skin elasticity. These procedures fail to address the issue of facial shape because they are incapable of reversing the facial soft-tissue atrophy that occurs with aging. Rather, by excising skin in areas most prone to atrophic sagging, they in effect “tailor” the skin to fit the shrunken framework. Present trends in facial rejuvenation are moving away from conventional excision and suspension procedures and toward the use of conservative skin excision, deep fascial–SMAS manipulation, volume restoration, and modification of facial animation (via chemodenervation). Dermal and subcutaneous fillers, used either alone or as an adjunct to surgical and nonsurgical facial rejuvenation techniques, are a logical and effective treatment choice for “lifting and filling” the facial soft tissues. The facial soft tissue remodeling that might be expected to occur in response to the implant of volume replacers could theoretically result in undesirable cosmetic changes and loss of effect over time. However, to date there is no clinical evidence to suggest that tissue remodeling has a significant impact on the efficacy of volume-enhancement techniques currently used in clinical practice. For those surgeons who do not wish to use fat transplants, new filler materials for volume augmentation offer the prospect of possibly more predictable (albeit temporary) aesthetic outcomes.¹⁵ Moreover, volume augmentation of areas of loss of facial fullness can be complemented by microliposuction of the hypertrophic fat pockets.¹⁶ In this way, the primary goal in facial rejuvenation—restoration of a youthful 3-D facial topography—may be realized. ■

References

1. Bartlett SP, Grossman R, Whitaker LA. Age-related changes of the craniofacial skeleton: an anthropomorphic and histologic analysis. *Plast Reconstr Surg* 1992;90:592-00.
2. Pessa JE, Zadoo VP, Yuan C, Ayedelotte JD, Cuellar FJ, Cochran CS, et al. Concertina effect and facial aging: nonlinear aspects of youthfulness and skeletal remodeling and why perhaps infants have jowls. *Plast Reconstr Surg* 1999;103:635-644.

3. Hamra ST. The role of orbital fat preservation in facial aesthetic surgery. *Clin Plast Surg* 1996;23:17-28
4. Donofrio LM. Fat distribution: a morphologic study of the aging face. *Dermatol Surg* 2000;26:1107-1112.
5. Little JW. Volumetric perceptions in midfacial aging with altered priorities for rejuvenation. *Plast Reconstr Surg* 2000;105:252-266.
6. Coleman SR. *Structural Fat Grafting*. St. Louis, MO: Quality Medical Publishing; 2004.
7. Gosain AK, Klein MH, Sudhakar PV, Prost RW. A volumetric analysis of soft-tissue changes in the aging midface using high-resolution MRI: implications for facial rejuvenation. *Plast Reconstr Surg* 2005;115:1143-1152.
8. Owsley JQ. Elevation of the malar fat pad superficial to the orbicularis oculi muscle for correction of prominent nasolabial folds. *Clin Plastic Surg* 1995;22:279-293.
9. Zimpler MS, Kokoska MS, Thomas JR. Anatomy and pathophysiology of facial aging. *Facial Plast Surg North Am* 2001;9:179-187.
10. Sherris DA, Larrabee WF. Anatomic considerations in rhytidectomy. *Facial Plast Surg* 1996;12:215-222.
11. Ellenbogen R, Youn A, Yamini D, Svehlak S. The volumetric face lift. *Aesth Surg J* 2004;24:514-522.
12. Lowe NJ, Wieder JM, Shorr N, Boxrud C, Saucer D, Chalet M. Infraorbital pigmented skin. Preliminary observations of laser therapy. *Dermatol Surg* 1995;21:767-770.
13. Guyuron B. The aging nose. *Dermatol Clin* 1997;15:659-664.
14. Özdemir R, Kilinc H, Ünlü E, Ca_ri Uysal A, Sensöz O, Nazmi Baran C. Anatomicohistologic study of the retaining ligaments of the face and use in face lift: retaining ligament correction and SMAS placcation. *Plast Reconstr Surg* 2002;110:1134-1147.
15. Rohrich RJ, Rios JL, Fagien S. Role of new fillers in facial rejuvenation: a cautious outlook. *Plast Reconstr Surg* 2003;112:1899-1902.
16. Coleman SR. Facial recontouring with lipostructure. *Clin Plast Surg* 1997;24:347-367.

This supplement is funded through sponsorship by Q-Med.

Sydney Coleman receives royalties from Byron Medical and is an unpaid consultant for Medicis; he has no financial interest in Q-Med.

Reprint requests: Sydney Coleman, MD, 44 Hudson Street, New York, NY 10013.

Copyright © 2006 by The American Society for Aesthetic Plastic Surgery, Inc.

1090-820X/\$32.00

doi:10.1016/j.asj.2005.09.012